


Junctional Hemorrhage Control



MSG Montgomery
August 8, 2011



Hemorrhage- A Look Back: Mogadishu, 1993



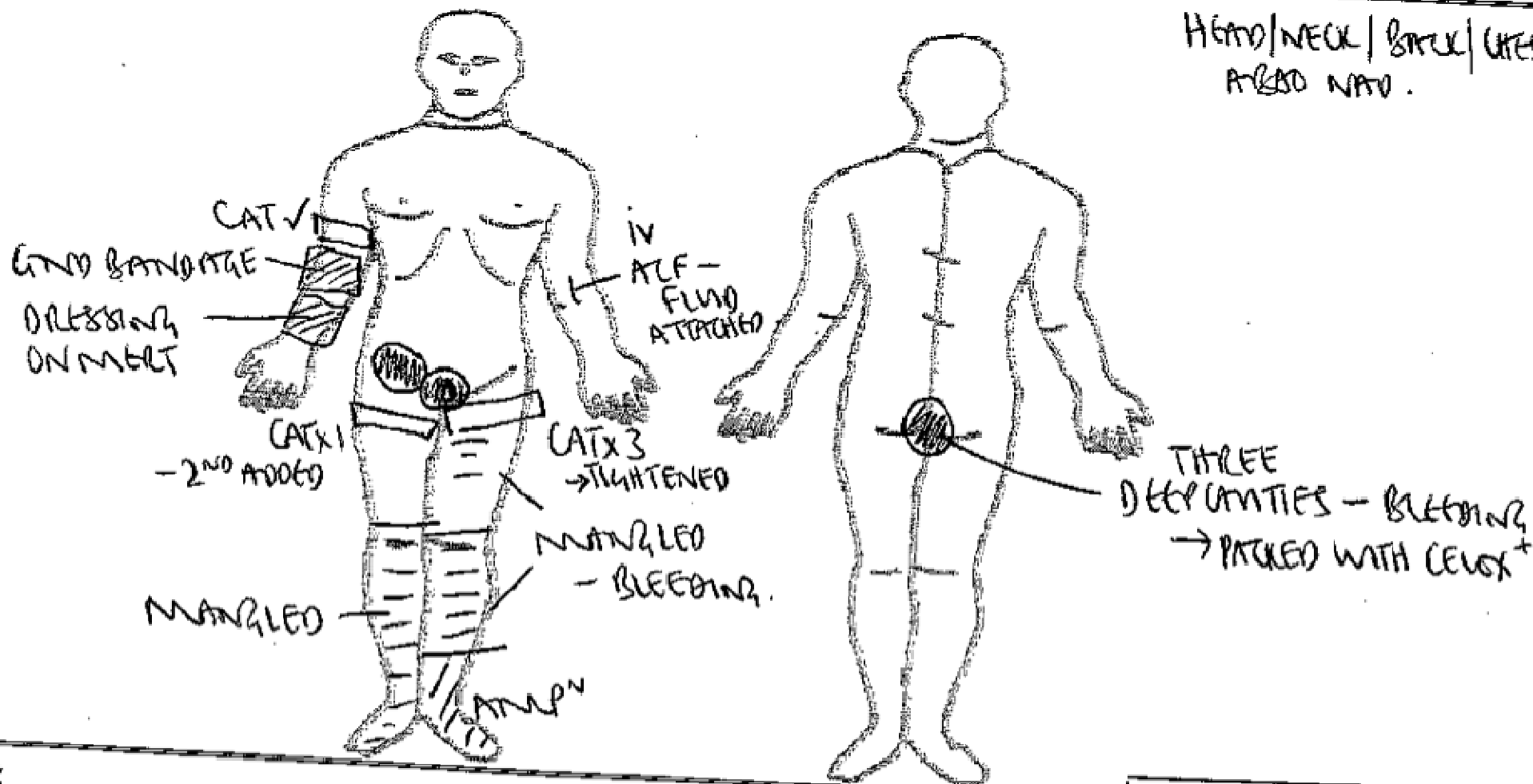
- **CPL Jamie Smith injury – exsanguination from groin injury too proximal for a tourniquet.**
- **An injury pattern we have since been attempting to solve for TCCC**



Recent Injury Examples

EXCERPT FROM HEALTH CARE RECORD

HEAD/NECK/BACK/ CHEST/
ARMS AND WRISTS.



-excerpt of a health care record of a case submitted by COL Kragh



Preventable Death

“In 6 months there were over 1000 IEDs found in the Sangin area by 3/5 Marines. Additionally, 3/5 Marines suffered over 200 casualties and 29 KIA in the same time. Many of these Marines had severe amputations that may have benefitted from proximal hemorrhage control. ”

Keith S. Gates, M.D.
LT (FMF/DV/FPJ), MC, USNR
Assistant Battalion Surgeon
1/23 Marines (FWD)
FOB Delaram, Afghanistan



Requirement

- USAMRMC posted request for information for device ideas that could potentially stop bleeding at compressible sites where regular tourniquets cannot be applied.
 - W81XWH-RFI-003, 03 MAR 2009
- 1) Will be able to occlude deep bleeding from intracavitary hemorrhage, including parenchymal injuries. As a minimum, the device should stop bleeding at compressible sites where standard tourniquets cannot be applied;
 - 2) Can be applied easily in a tactical environment with a minimum level of familiarization;
 - 3) Must not slip during tightening or following application;
 - 4) Be capable of easy release and re-application;
 - 5) Be of light weight;
 - 6) Have long shelf life, low cost and low cube.



Key Premise

If we are going to ask a medic or corpsman to perform a medical intervention on the battlefield, we want to be very confident that it will benefit the casualty.

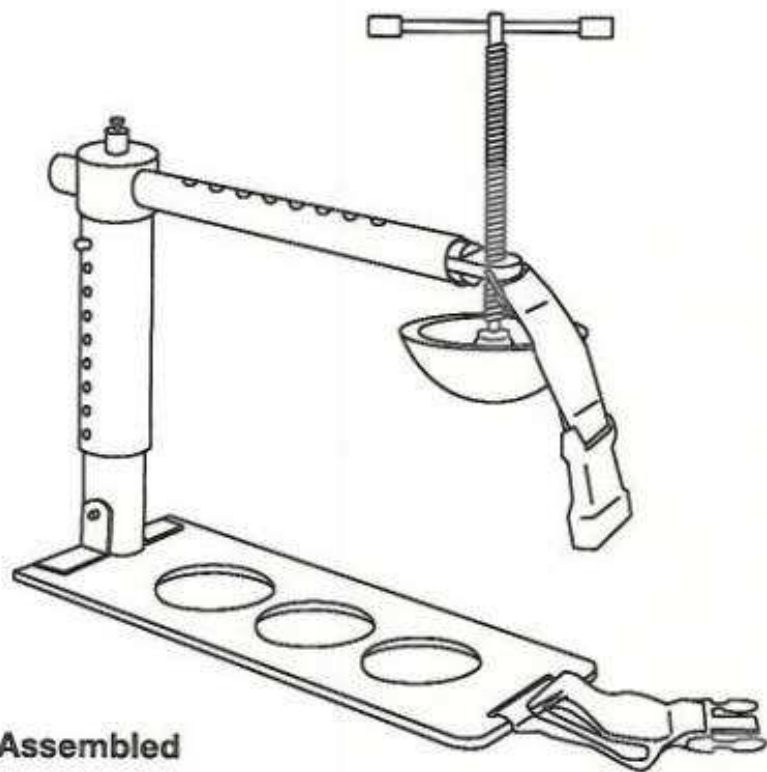
Anything we ask a medic or corpsman to perform must be have a training and equipping solution that is relatively easy to implement.



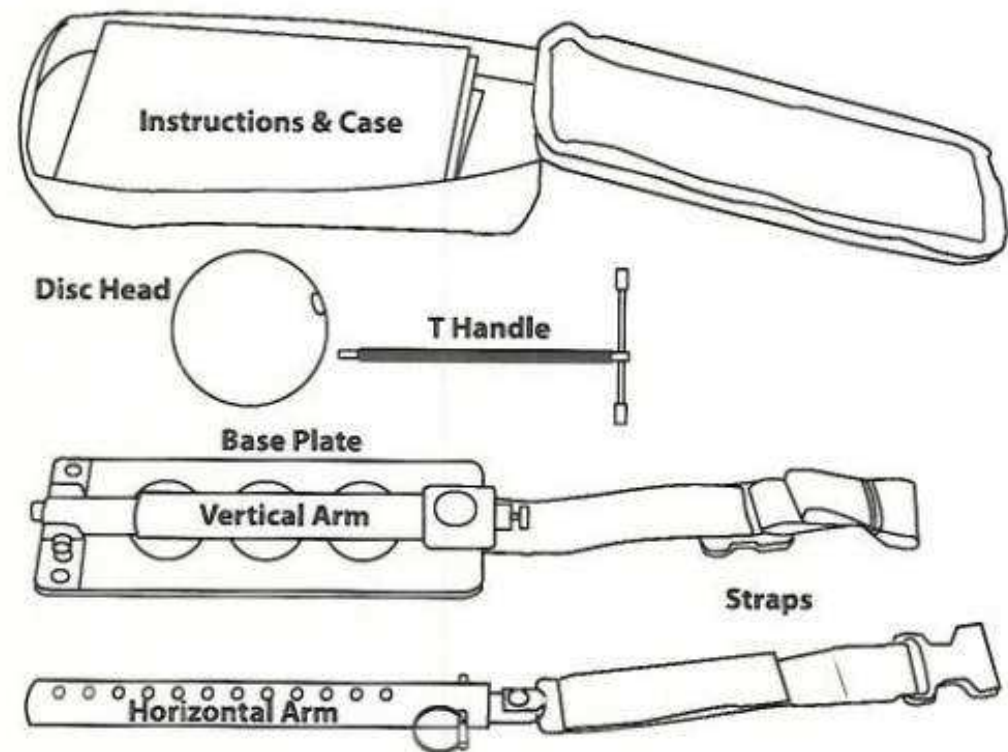


Combat Ready Clamp





Assembled





FDA Approved Target Application Points

- **INGUINAL:** Direct pressure over packed inguinal injury site.
- **PELVIC:** Pressure point midway between anterior superior iliac spine and pubic tubercle (occludes external iliac artery).
 - Recommend using pubic symphysis instead of tubercle.



Unapproved Target Application Points

- **ABDOMINAL:** Pressure point at or just below umbilicus (occludes both internal and external iliac arteries bilaterally)
- **AXILLARY:** Concept pending



Current Fielding & Use

- SOF
 - U.S. Army Special Missions Unit (SMU)
 - 75th Ranger Regiment
 - U.S. Navy SMU
- Memorial Hermann Hospital Life Flight, Houston, TX



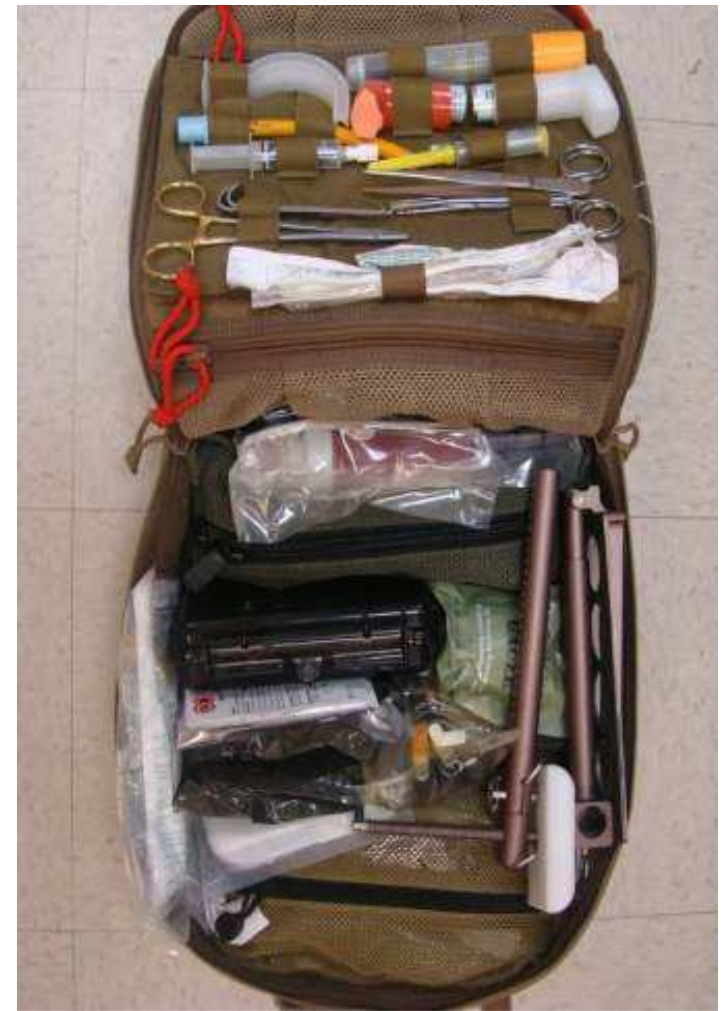Human Use

One reported use on an local national casualty in theater with no follow-on survival or outcome data.



Equipping & Carrying

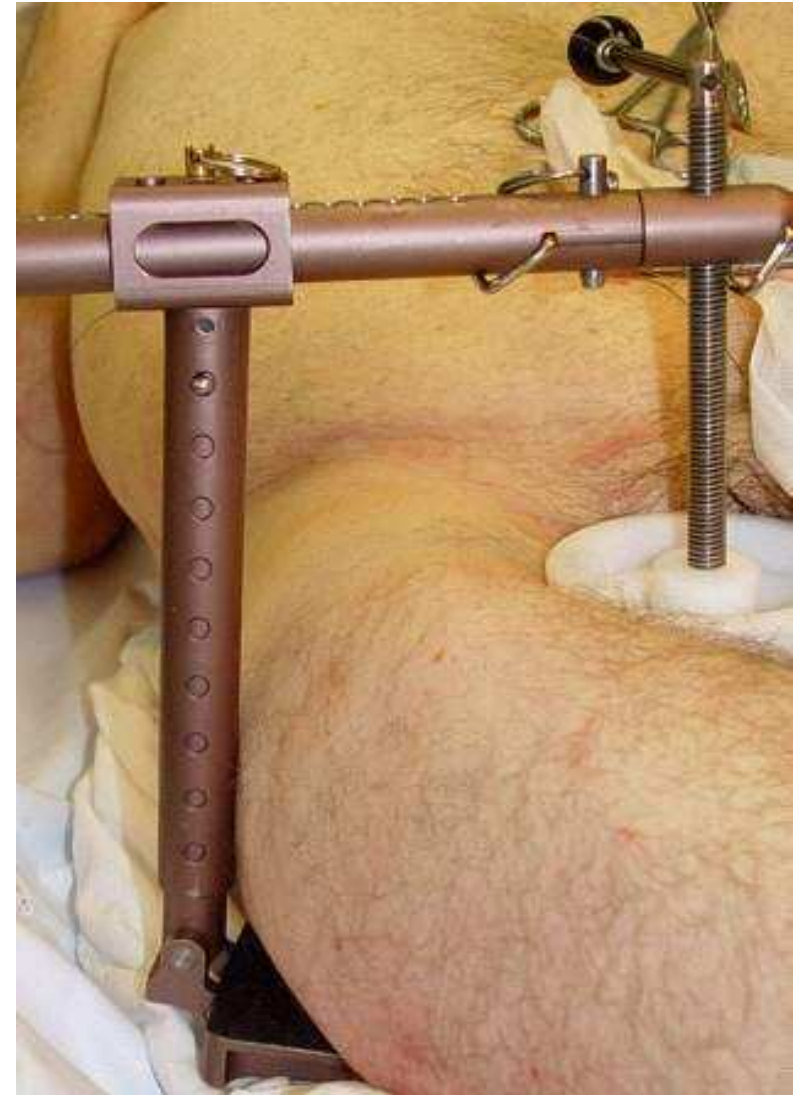- Medic/Corpsman carried device
- Aidbag-based
 - Partially broken-down
 - 1.5 lbs





Testing Conducted

- Massive bleeding (perfused) models in fresh human cadavers at Wake Forest University School of Medicine
- Publication Pending:
Emergency Inguinal Clamp Controls Prehospital Hemorrhage in Cadaver Model,
Kragh, et al





Proposed Testing

- Effectiveness of a junctional hemorrhage control device as applied by military personnel trained in a combat zone.
 - Principal Investigators:
 - LT Keith S. Gates, MD, USNR
 - Col Edward L. Fieg, MD, USAF
 - A prospective, randomized, crossover, observational study of the application of device in a controlled setting.
 - Each individual will apply device on 5 male test subjects. Blood flow evaluated by color doppler ultrasound and palpable pulses.



Potential Issues

- Stabilization during transport
- Device Impact with Pelvic Fracture
- Clinical decision-making on the right time and place to apply device
 - NOT exclusive to this device!!!!
 - Applies to virtually ALL TCCC concepts.



Bottom Line

- FDA approved
- Currently fielded
- No other options to meet current need



Bleeding Control

Tactical Field Care - Current

4. Bleeding

- a. Assess for unrecognized hemorrhage and control all sources of bleeding. If not already done, use a CoTCCC-recommended tourniquet to control life-threatening external hemorrhage that is anatomically amenable to tourniquet application or for any traumatic amputation. Apply directly to the skin 2-3 inches above wound.

- b. For compressible hemorrhage not amenable to tourniquet use or as an adjunct to tourniquet removal (if evacuation time is anticipated to be longer than two hours), use Combat Gauze as the hemostatic agent of choice. Combat Gauze should be applied with at least 3 minutes of direct pressure. Before releasing any tourniquet on a casualty who has been resuscitated for hemorrhagic shock, ensure a positive response to resuscitation efforts (i.e., a peripheral pulse normal in character and normal mentation if there is no traumatic brain injury (TBI)).

- c. Reassess prior tourniquet application. Expose wound and determine if tourniquet is needed. If so, move tourniquet from over uniform and...



Bleeding Control


Tactical Field Care - **Proposed**

4. Bleeding

(keep 4a. as is)

- b. For compressible hemorrhage not amenable to tourniquet use or as an adjunct to tourniquet removal (if evacuation time is anticipated to be longer than two hours), use Combat Gauze as the hemostatic agent of choice. Combat Gauze should be applied with at least 3 minutes of direct pressure. Before releasing any tourniquet on a casualty who has been resuscitated for hemorrhagic shock, ensure a positive response to resuscitation efforts (i.e., a peripheral pulse normal in character and normal mentation if there is no traumatic brain injury (TBI). **If a lower extremity wound is not amenable to tourniquet application and cannot be controlled by hemostatics/dressings, consider immediate application of mechanical direct pressure including CoTCCC recommended devices such as the Combat Ready Clamp™ (CRoC).**

Questions?





Recent Injury Examples

Facility	Facility Notes
PRE-HOSPITAL CARE	20 y/o S/P dismantled IED blast with multiple injuries, including BLE traumatic amputations (high LLE), perineal wounds. CAT TQ to BLE by ground medics; Morphine 10 mg IM. Care by MERT. GCS=3, no airway, no BP. RSI done. I/O to sternum and left humeral head; blood resuscitation begun, with PRBCs 3 u, FFPs 3 u. Pulse up to 200, with RR=6. Pelvic sling.
BASTION	Received from MERT at 1241 on 4/24, intubated and sedated. Sulcus sign on left chest. FAST (negative). CXR=Negative. Pelvis: Complex, unstable pelvic fracture. To OR at 1307 (no CT) for: Ex-lap for proximal vascular control with cross-clamping of common iliac veins (No organ injuries, sigmoid bowel divided and left discontinuous) and TAC, right chest tube; I&D wounds left arm and forearm with left forearm fasciotomy; completion amputation BLE; left chest drain, pelvic ex-fix and debridement of perineum with scrotal repair; washout OU. CT Traumagram: Head -No intracranial injuries; Chest-CT in place; Abdomen/Pelvis [®] No solid organ injury identified, retro-peritoneal blood around right kidney but no active bleeding, massive soft tissue disruption within pelvis; Spine-No C-T-L spine fracture, but gas from sacral fracture; high BLE amputations with disrupted unstable pelvis. TO ICU for post-op care, intubated and sedated. BP 151/76, HR=99. BLOOD: PRBCs 37 u, FFPs 37 u, Cryo 3 un, Platelets 7 six-packs, TXA in OR.
CCATT/AE	REPORT
BAGRAM	Arrived ED at 0905 on 4/25, intubated and sedated; GCS=3T. BO: 82/43, HR=92, Temp=101.8 (? Method). No C-collar. Open abdominal wound with TAC and pelvic ex-fix. BLOOD: PRBCs 2 u, FFPs 2 u. To OR at 0940 for: second look laparotomy with TAC; (Ortho) Exploration and sympathectomy of ulnar portion of deep arch and common digitals. 2)Exploration of digital arteries of R/5 fingers. 3) Embolectomy of common digital to R/M finger. 4) Vein interposition/reconstruction of radial digital to 5 finger.; (Vascular) exploration of left brachial artery through preexisting arm incision. Washout of left arm wounds and wound vac placement. To ICU at 1935 for post-op care, intubated and sedated. 4/26 Lovenox 40 mg QD started. BLOOD: FWB 2 u; FFPs 2 u. Noted with worsening redness to trunk area, Benadryl 50mg IV per MD order given. Moved to CCATT litter, uneventful; no other changes.
CCATT/AE	REPORT: According to 3899, no major in-flight events
LRMC	Admitted to ICU from CCATT on 4/26, intubated and sedated. To OR for wound washouts; BLE show progressive myonecrosis with extension of injuries in the perineum and peri-anal areas.4/27: Attempted SBT; unable to wean. 4/28: TO OR for further washouts. Progressive myonecrosis required left hip disarticulation. Screening US for DVT: negative BLE. Suspected fungal infections per cultures. 4/29: Moving BUE when off sedation.
CCATT/AE	REPORT
NNMC	Arrived



Manufacturer's Guidelines

DETERMINING IF A CLAMP IS NEEDED. A Combat Ready Clamp (CRoC™) is placed in the inguinal area to stop circulation to the pelvic and femoral region when a casualty is in danger of bleeding to death from wounds that cannot be controlled by traditional bandages or tourniquets. A clamp is only used when a casualty is in danger of bleeding to death from an inguinal wound. Use of prior devices does not preclude clamp use.

WARNING: This device is **not to be used for wounds to the head, neck, abdomen and chest.**